

# Biological and esthetic outcome of immediate dental implant with the adjunct pretreatment of immediate implants with platelet-rich plasma or photofunctionalization: A randomized controlled trial

Shahid Ahmad Shah, Balendra Pratap Singh, Jitendra Rao, Lakshya Kumar, Mayank Singh, Punit Kumar Singh  
Department of Prosthodontics, Faculty of Dental Sciences, King George's Medical University, Lucknow, Uttar Pradesh, India

## Abstract

**Aim:** The purpose of the study was to assess biological and esthetic outcomes of immediate dental implant in esthetic zone with the adjunct pretreatment of immediate implants with photofunctionalization or platelet-rich plasma in comparison to standard tapered root form implant without pretreatment.

**Settings and Design:** Patients visiting department of Prosthodontics of a tertiary care health Institution. Design of the study was randomized controlled trial.

**Materials and Methods:** Ninety subjects who required replacement of maxillary anterior teeth immediately after extraction were selected and randomly divided into three groups: control group and two case groups. Two case groups were treated with immediate implants with pretreatment with Photofunctionalization (PF group) or platelet-rich plasma (PRP group). Delayed loading protocol was followed with prosthesis given after 6 months. Follow-up was performed at 2<sup>nd</sup> and 4<sup>th</sup> weeks and 2, 4, 6, and 12 months ( $P < 0.05$ ). Biological outcomes (mean marginal bone loss, implant stability), esthetic outcome (pink esthetic score and white esthetic score), and success and survival rate were evaluated.

**Statistical Analysis Used:** Outcomes were compared using one-way ANOVA, while intragroup changes with baseline and follow up were assessed using repeated-measures ANOVA. Statistical analyses were performed using Statistical Package for Social Sciences version 25.0 (SPSS Inc., Chicago, IL, USA). The level of significance was set at  $< .05$ .

**Results:** Mean marginal bone loss was not significantly different in PF group and PRP group than the control group. PF group and PRP group showed significantly greater implant stability as compared to the control group. Pink and white esthetic scores were not significantly different among groups.


**Conclusion:** Pretreatment of commercial dental implants with PF or PRP exhibited a statistically significant difference in implant stability but not with other outcomes.

**Keywords:** Dental implants, immediate dental implant, platelet-rich plasma, randomized controlled trial

**Address for correspondence:** Dr. Balendra Pratap Singh, Department of Prosthodontics, Faculty of Dental Sciences, King George's Medical University, Lucknow, Uttar Pradesh, India.

E-mail: balendra02@yahoo.com

**Submitted:** 14-May-2021, **Revised:** 02-Aug-2021, **Accepted:** 07-Sep-2021, **Published:** 09-Nov-2021

Access this article online	
Quick Response Code:	Website: <a href="http://www.j-ips.org">www.j-ips.org</a>
	DOI: 10.4103/jips.jips_217_21

This is an open access journal, and articles are distributed under the terms of the Creative Commons Attribution-NonCommercial-ShareAlike 4.0 License, which allows others to remix, tweak, and build upon the work non-commercially, as long as appropriate credit is given and the new creations are licensed under the identical terms.

**For reprints contact:** WKHLRPMedknow\_reprints@wolterskluwer.com

**How to cite this article:** Shah SA, Singh BP, Rao J, Kumar L, Singh M, Singh PK. Biological and esthetic outcome of immediate dental implant with the adjunct pretreatment of immediate implants with platelet-rich plasma or photofunctionalization: A randomized controlled trial. J Indian Prosthodont Soc 2021;21:348-55.

## INTRODUCTION

Restoration of edentulous area using dental implants has been well-documented and shown to have predictable outcomes.<sup>[1,2]</sup> Literature revealed that alveolar process undergoes significant resorption and volume loss after extraction or tooth loss due to other reasons.<sup>[3]</sup> Few authors have advocated treatment procedures involving immediate dental implant placement to limit such resorptive process;<sup>[4]</sup> however, few preclinical studies have shown contradictory results that placement of immediate implant does not prevent resorptive bone changes.<sup>[5,6]</sup> The role of dental implant placement in an immediate extraction socket is still controversial and lacks sufficient evidence.<sup>[7-9]</sup> Early implant failure is due to inadequate osseointegration and needs bioactive surface treatment which may enhance osseointegration after implant placement and validates a long-standing bone-to-implant contact (BIC) without considerable marginal bone loss.<sup>[10]</sup>

There are a plethora of new surface treatments which help to rehabilitate patients in critical clinical situations with predictable success rates.<sup>[11]</sup> These treatments encompass ion beam-assisted deposition, sputter coating, pulsed laser deposition, electrostatic spray deposition, photofunctionalization (PF), platelet-rich plasma (PRP), etc.<sup>[11]</sup>

PF is a process in which implants are subjected to UV radiation. UV treatment enhances the osteoconductivity,<sup>[12,13]</sup> reduces the degree of surface hydrocarbon, and increases surface energy and wettability.<sup>[14-18]</sup> This study included PF of implant surface because it had shown to increase the strength of bone-implant integration, which is simple, highly efficient, and economical.<sup>[14]</sup> Studies suggested that PF may help in advancement of treatment with dental implant with better outcomes.<sup>[17-20]</sup>

PRP promotes healing of socket by increasing vascularity in the first 20 days. Studies supporting the use of PRP are based on regenerative potential of soft and hard tissue.<sup>[21-24]</sup> However, in the field of dentistry; there is still a lack of consensus in this regard due to various disparities in experimental design and controls.<sup>[22]</sup>

Evidence-based dentistry is lacking in controlled clinical trials regarding the use of photofunctionalized dental implant or PRP as pretreatment in immediate implant placement. Hence, this study was planned to assess biological and esthetic outcomes of immediate dental implant in maxillary anterior area with adjunct pretreatment of immediate implants with PRP or PF in comparison to standard tapered root form implant.

## MATERIALS AND METHODS

This assessor and statistician blinded parallel randomized controlled trial (March 2015 to November 2017) was conducted in a tertiary care referral institution after ethical approval from the institutional ethical committee (71<sup>st</sup> ECM IIB Thesis//P47). Clinical trial registration number was CTRI/2018/06/014562. Subjects were selected from referred patients for replacement of anterior tooth/teeth with poor prognosis immediately after extraction. Written informed consent was obtained from all subjects as per the Declaration of Helsinki. CONSORT reporting guideline<sup>[25]</sup> was used in manuscript preparation.

The sample size was calculated on the basis of variation in marginal bone loss in control and case groups by putting standard deviation at 1.7 and 1.9, respectively<sup>[26]</sup> and a difference of 2.25 considered to be clinically significant. Considering 95% confidence level and 80% power of study, the sample size was calculated to be 30 for each group.

### Inclusion criteria

1. Subjects  $\geq 18$  years
2. Able to provide consent
3. One or more teeth need to be extracted for immediate implant in maxillary anterior area (13–23)
4. Presence of healthy periodontium in adjacent teeth<sup>[27]</sup>
5. Minimum 1.5 mm bone must remain between dental implant and neighboring teeth as well as on facial side, and 0.5 mm bone must remain between implant and palatal side
6. At least 4 mm bone apical to root apex of extracting tooth.

### Exclusion criteria

1. Systemic diseases or metabolic disorders if any which may impact study, pregnant and lactating women
2. Currently smoker or quitted smoking <1 year ago
3. Parafunctional activities
4. Uncontrolled periodontal disease, caries, or clinical or radiographic signs of infection within two adjacent teeth
5. Current chemotherapy/radiotherapy or drugs that interfere with study.

Subjects were divided into three groups: Control group treated with standard tapered root form dental implant and two case groups in which implants were pretreated with adjunctive therapy of PF (group) or PRP (group). Alpha Dent (Active) tapered internal implant (Bokstrasse, Muenster) was used. It has aggressive thread, micro thread, curving at apical part, antirotational sulcus, and internal hexagon

2.4 mm. Implant of 3.75 × 11.5 mm diameter was chosen for all subjects after checking available bone as per inclusion and exclusion criteria. Subjects were randomly divided into any group through the opening of opaque sealed envelope in which sequence was generated using computer-generated random numbers. The study and rehabilitation protocols were standardized for all three groups.

Presurgical radiographic evaluation was done with the help of three-dimensional cone-beam computed tomography to evaluate the length and width of available bone and accordingly, dimensions of dental implants were selected for placement. Prophylactic medication of 2 g amoxicillin was given 1 h prior to surgery and atraumatic extraction of offending teeth was done using 2% lignocaine with adrenaline (1:80,000). During the surgical phase, implants were placed in extraction sockets after preparation of osteotomy site by sequential drilling protocol as recommended by manufacturer. Primary implant stability was gained by engaging palatal and apical portion of alveolar bone such that the axis of implant is in line with incisal edge of adjacent teeth or slightly palatal to that. After achieving primary implant stability (torque 35 Ncm), xenograft (Bio-oss, Geistlich Pharma AG, Wolhusen, Switzerland) was placed in space remain in the socket and above that, collagen membrane was placed (Bio-Gide Geistlich Pharma AG, Wolhusen, Switzerland).<sup>[28]</sup> Flap was sutured then with tension-free closure.

For PF, implants were subjected to chairside UV radiation of wavelength 253.7 nm in ultraviolet rays chamber (SK Dent) for 20 min followed by immediate implant placement in extraction socket.<sup>[12,13]</sup>

For PRP graft, about 30 ml venous blood was withdrawn from the subject and placed in a centrifugation machine in a vacutainer at 3500 rpm for 10 min. This separated PRP at the base of the vacutainer. When PRP was prepared, it was activated with 10% calcium chloride. The implant was then moistened all around with PRP solution and then placed in the osteotomy site.

Postoperative instructions were given to subjects which include use of ice pack, diet, and rinsing mouth with 0.2% chlorhexidine gluconate mouthwash twice a day. Follow-up included measurement of outcomes at specific time intervals. Outcomes were assessed by two calibrated blinded assessors (MS and PKS) at baseline (immediately after surgery) and follow-up.

- Marginal bone loss (baseline, 2, 4, 6, and 12 months)
- Implant stability (2<sup>nd</sup> and 4<sup>th</sup> weeks and 2, 4, 6, and 12 months)

- Esthetic outcome by pink esthetic score (PES)<sup>[29]</sup>/white esthetic score (WES) (6 months after prosthetic rehabilitation)<sup>[30,31]</sup>
- Success and survival rate (at completion of 12 months).

Delayed loading protocol was followed. Depending on the position of access hole, a screw or cement-retained prosthesis was planned after 3–6 months.

Assessment of marginal bone loss was done immediately after surgery (baseline) and at 2, 4, 6, and 12 months with help of intraoral periapical radiograph. Marginal bone loss was measured by using customized positioning stent which was used to repeat the exact position of implant with reference to X-ray tube (Gomex Dental X-ray system). XCP extension cone paralleling film holding device was used to increase dimensional accuracy of dental X-ray images. Tagged image file format was created from a dataset of images and ImageJ software (ImageJv. 1.46r, National Institutes of Health) was used to measure marginal bone loss.<sup>[32-36]</sup> Image was corrected as per the known measurement of implant platform. Distance between implant platform and bone level was measured. If the bone is above the implant platform, then the distance between implant platform and crest of bone was measured. If the bone is below the implant platform, then the distance between implant platform and first BIC was measured. These two were assigned positive and negative values, respectively. All distances were measured linearly in millimeters and in vertical direction. It was measured on the mesial side as well as on the distal side and the mean was taken for statistical analysis.

Implant stability was measured using a resonance frequency analyzer (Osstell, Integration Diagnostics Pvt Ltd) by inserting peg in dental implant and placing the tip (without touching the peg) of analyzer at 45° to the peg. Value of implant stability in ISQ was measured in buccal and palatal aspects and the mean was used for statistical analysis.<sup>[32,37]</sup> Esthetic outcome was measured by combining pink and White Esthetic Score at baseline and 6 months after prosthetic rehabilitation. It was done by two Prosthodontists who were blinded from group allocation, and one has used this index in the previously published study.<sup>[32]</sup>

The success and survival was measured by International Congress of Oral Implantologists (ICOI) Pisa consensus conference into success (optimum health), satisfactory survival, compromised survival and failure (clinical or absolute failure) on the basis of clinical conditions pain (absent, absent in function, sensitivity in function, pain in function), mobility (present or absent), radiographic

crestal bone loss, probing depth and peri-implant disease.<sup>[38]</sup> Probing depth was measured at four aspects of each implant: mesial, distal, facial, and palatal. It was hypothesized that there will be no difference in marginal bone loss, implant stability, esthetic outcome, success and survival rate in PF, PRP and control group subjects.

The results were analyzed using descriptive statistics and making comparisons among various groups. Discrete (categorical) data were summarized as proportions and percentages and quantitative data as mean ± standard deviation. Marginal bone loss, implant stability, and esthetic outcomes were compared using one-way ANOVA, while intragroup changes with baseline and onward according to time points were assessed using repeated-measures ANOVA. Statistical analyses were performed using Statistical Package for Social Sciences IBM Corp. Released 2017. IBM SPSS Statistics for Windows, Version 25.0. (Armonk, NY: IBM Corp.). The level of significance was chosen <0.05.

## RESULTS

The basic characteristics of subjects are summarized in Table 1 and the flow diagram from enrolment to analysis is presented in Figure 1. The overall proportion of male (56%) was higher than female (44%). While comparing missing tooth, central incisor (53%) was the most common missing tooth followed by lateral incisors (43%) and canine (4%).

Table 2 shows a statistically significant difference in mesial marginal bone loss at 2 months among three groups ( $P < 0.001$ ), but no significant difference was found during follow-up. Intragroup comparison showed that mesial marginal bone loss was significantly increased during follow-up in all groups ( $P < 0.001$ ).

**Table 1: Basic characteristics of subjects**

Characteristics	Number of subjects (n=84), n (%)
Gender	
Males	47 (55.95)
Females	37 (44.04)
Missing tooth	
Central incisor	45 (53.57)
Lateral incisor	36 (42.85)
Canine	3 (3.57)

**Table 2: Mesial marginal bone loss (in millimeters) comparison among groups**

Bone loss (mesial)	Mean±SD						One-way ANOVA	
	PF group		Control group		PRP group		F	P
2 months	1.23	0.13	1.01	0.16	1.00	0.11	11.50	<0.001
4 months	1.48	0.15	1.30	0.17	1.30	0.13	5.92	0.007
6 months	1.68	0.15	1.63	0.10	1.54	0.14	3.44	0.044
12 months	1.87	0.15	1.85	0.12	1.80	0.16	0.71	0.497
Intragroup (repeated measures)	F=390.13, P<0.001		F=180.61, P<0.001		F=228.62, P<0.001			

SD: Standard deviation, PRP: Platelet-rich plasma, PF: Photofunctionalization

No significant distal marginal bone loss was found during intergroup comparison at 2 months and during follow-up in Table 3. For intragroup comparison, distal marginal bone loss was significantly increased during follow-up from 2 months to 12 months in all groups ( $P < 0.001$ ) Kappa linear coefficient value of 0.72 was found between mesial and distal crestal bone loss for assessor.

Table 4 shows statistically significant difference in mean marginal bone loss among PF group, control group, and PRP group at 2 months, but not at 4, 6, and 12 months. Table 4 also shows that for each group mean marginal bone loss was significantly increase in each follow-up. Mean marginal bone loss is ranged from 1.75 to 1.78 mm which is not of clinical significance.

At 2<sup>nd</sup> and 4<sup>th</sup> weeks, no significant difference in implant stability was found among any groups. At 2, 4, 6, and 12 months, a statistically significant difference in implant stability was found in PF group and PRP group in comparison to control group ( $P < 0.001$ ) and this difference was statistically significant in intragroup comparison as well ( $P < 0.001$ ) [Table 5].

Esthetic score among groups exhibited statistically nonsignificant difference [Table 6]. Success and survival rates were higher in the control group (96.42%) than the PF group (92.59%) and PRP group (93.01%) [Table 7]. One implant in PF group showed satisfactory survival because the marginal bone loss was 2.1 mm. The reason of failure of one implant from each group was uncontrolled progressive bone loss and one implant in each from PF and PRP group was uncontrolled exudate.

## DISCUSSION

This study found nonsignificant difference in mean marginal bone loss and significantly higher implants stability in subjects in which implants were treated with photofunctionalization or PRP graft than subjects without any pretreatment. PF involves bioactivity and osseointegration by altering titanium dioxide on the surface. UV-treated titanium surfaces are superhydrophilic, electropositive, thereby attaining higher BIC,<sup>[13,14,16]</sup> but in this study, nonsignificant difference in the



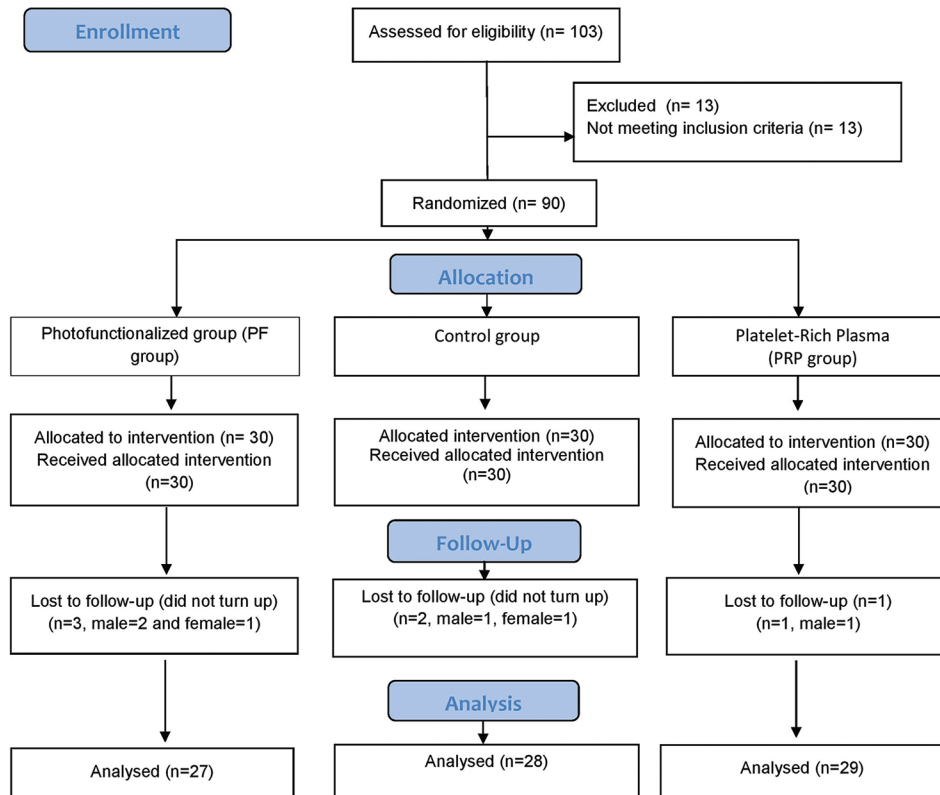


Figure 1: Flowchart according to CONSORT guidelines

Table 3: Distal marginal bone loss (in millimeter) comparison among groups

Bone loss (distal)	Mean±SD			One-way ANOVA	
	PF group	Control group	PRP group	F	P
2 months	0.99 (0.13)	0.89 (0.14)	0.91 (0.12)	2.06	0.144
4 months	1.26 (0.10)	1.15 (0.13)	1.17 (0.13)	2.62	0.089
6 months	1.49 (0.11)	1.44 (0.10)	1.44 (0.16)	0.67	0.519
12 months	1.68 (0.12)	1.66 (0.08)	1.70 (0.16)	0.24	0.787
Intragroup (repeated measures)	F=209.76, P<0.001	F=309.21, P<0.001	F=196.56, P<0.001		

SD: Standard deviation, PRP: Platelet-rich plasma, PF: Photofunctionalization

Table 4: Mean marginal bone loss (in millimeter) comparison among groups

Bone loss (mean)	Mean±SD			One-way ANOVA	
	PF group	Control group	PRP group	F	P
2 months	1.11±0.10	0.95±0.11	0.95±0.08	10.54	<0.001
4 months	1.37±0.12	1.23±0.13	1.23±0.11	5.78	0.007
6 months	1.59±0.12	1.53±0.09	1.49±0.12	2.30	0.116
12 months	1.78±0.13	1.76±0.09	1.75±0.12	0.15	0.864
Intragroup (repeated measures)	F=337.62, P<0.001	F=447.88, P<0.001	F=492.74, P<0.001		

SD: Standard deviation, PRP: Platelet-rich plasma, PF: Photofunctionalization

Table 5: Implant stability comparison at different time intervals among groups

Stability	Mean±SD			One-way ANOVA	
	PF group	Control group	PRP group	F	P
2 weeks	39.08±1.88	39.00±1.79	38.33±1.56	0.66	0.524
4 weeks	41.00±1.95	40.82±1.66	40.08±1.56	0.93	0.405
2 months	53.67±3.11	48.55±2.58	51.25±1.42	12.31	<0.001
4 months	65.25±2.99	53.73±2.24	61.75±1.82	68.78	<0.001
6 months	69.83±1.47	61.09±1.58	68.25±1.54	105.17	<0.001
12 months	72.08±1.38	65.09±1.76	71.17±1.34	73.20	<0.001
Intragroup (repeated measures)	F=665.42, P<0.001	F=637.98, P<0.001	F=1962.06, P<0.001		

SD: Standard deviation, PRP: Platelet-rich plasma, PF: Photofunctionalization

**Table 6: Esthetic outcome (pink esthetic score and white esthetic score) comparison among groups**

PF group	Mean±SD		One-way ANOVA	
	Control group	PRP group	F	P
13.25±0.87	13.18±0.75	13.08±0.90	0.12	0.889

SD: Standard deviation, PRP: Platelet-rich plasma, PF: Photofunctionalization

**Table 7: Success and survival rate among groups**

Health scale	PF group	Control group	PRP group
Success	24	27	27
Satisfactory survival	1	0	0
Compromised survival	0	0	0
Failure	2	1	2
Percentage	92.59%	96.42%	93.01%

PRP: Platelet-rich plasma, PF: Photofunctionalization

mean marginal bone loss was found in PF or PRP group compared to the control group. This difference is not of clinical significance range.

Decreased mean marginal bone loss in PRP group was found in comparison to control group. Published literature suggested that PRP is a rich source of autologous growth factors such as vascular endothelial growth factor (VEGF), platelet-derived growth factor (PDGF), and transforming growth factor (TGF), which had more of an osteoblastic effect on bone remodeling leading to less marginal bone loss.<sup>[22,39]</sup> It is in compliance with the study by Thor *et al.*<sup>[40]</sup> who demonstrated reduced marginal bone resorption with PRP graft, but the difference was not significant.

Radiographic variability during evaluation of marginal bone loss between mesial and distal sites around implants can be attributed to uneven alveolar ridge consequently leading to the placement of some implants on the ascending or descending alveolar ridge.<sup>[41]</sup> These conditions may have resulted in variation in implant–abutment junction positions mesiodistally in relation to the bone level.

Implant stability in PF group was higher than control group and it is supported by few scientific literature.<sup>[17,18,20,40]</sup> Kitajima and Ogawa<sup>[42]</sup> had advocated that PF results in greater implant stability with two-stage surgical procedures. In immediate implant placement, robust stability at the initial time period compensates inadequate primary stability and consequently leads to consistently high implant stability. However, certain studies have reported no significant differences in implant stability with or without photofunctionalised implants.<sup>[43]</sup> Although the difference in implant stability is statistically significant among groups, published literature did not find any clinically significant difference in terms of stability or function at the value of 72, 65, and 71 ISQ.<sup>[44,45]</sup>

Marx *et al.*<sup>[39]</sup> found that PRP because of its rich source of autologous growth factors such as VEGF and PDGF had more of an osteoblastic effect on bone remodeling even in few animal experiments, but few contradictory studies are also published.<sup>[21]</sup> Despite contradictory results, the use of PRP along with endosseous dental implants had exhibited considerable bone remodeling.<sup>[46]</sup>

Thor *et al.*<sup>[40]</sup> found significantly greater implant stability placed in the anterior maxilla at sites where PRP was used than not used, but no differences were found for implants placed in posterior regions. They concluded that differences cannot be attributed to PRP but may be due effect of different types of bone used as graft.

Esthetic outcome did not significantly different among groups because it was observed that esthetic depends on the thickness of gingival biotype like thick or thin. This result may be due to selection criteria with intact facial bone, medium to thick tissue biotype and fabrication of prosthesis by the same technician.<sup>[46]</sup> There are limited studies in which PES/WES index was used for esthetic evaluation of anterior immediate implants.<sup>[46]</sup> These indices are more reliable, objective, and quantifiable for assessing esthetic outcome as compared to the papillary index.<sup>[31]</sup>

Success of PF is proposed to be due to the generation of superhydrophilic (contact angle less than 5°) surface after ultraviolet treatment, which results in greater BIC (2–3 times) as compared to untreated implants. This superhydrophilic surface results in greater attachment of osteogenic cells with implants as compared to without any pretreatment. Success and survival rates in PRP graft are proposed to be due to different growth factors. The protein stratum consists of a fibrin mesh and growth factors that cover the implant surface and allows the initial interaction of surrounding tissues with implant surface. It also enhances cellular proliferation, attachment, differentiation, and bone matrix deposition.<sup>[22]</sup> However, this study did not find better success and survival rate in pretreatment subjects. The reasons were uncontrolled progressive bone loss and uncontrolled exudate which may be due to infection that occurred in those patients and statistical analyses used were of intent to treat type. Hence, large cohort and increased duration of follow-up might help to get better informed decision.

Considering the outcomes observed, a null hypothesis which was proposed to find no difference among three groups exists regarding marginal bone loss, implant stability, esthetic outcome, and success and survival rate was rejected.

The limitations of this study include small sample size, shorter duration of follow-up, and inability to assess buccal and lingual bone loss due to inherent disadvantage of the radiographic technique employed to access the bone loss. In addition, the PES/WSE index used is in context to facial esthetics, where PES/WES score is only a small component. Hence, this index is far less significant in patients with a low lip line. Future studies involving large cohort with a longer duration of follow-up and employment of advance radiographic imaging modalities may overcome the limitations of the present study and will help in generalizability of the finding.

## CONCLUSIONS

PF and PRP surface treatment of commercial dental implants may show better statistically significant outcomes in immediate implant placement in anterior maxillary area in comparison to standard tapered root from implant without any pretreatment but lack in clinical significance. Furthermore, the cost and morbidity to a patient for the adjunct use of PF and/or platelet-rich-plasma (drawing of blood) are not outweighed by the benefits of this technique.

## Financial support and sponsorship

Nil.

## Conflicts of interest

There are no conflicts of interest.

## REFERENCES

- Bedrossian E, Bedrossian EA. Fundamental principles for immediate implant stability and loading. *Compend Contin Educ Dent* 2019;40:i1-8.
- Buser D, Sennerby L, De Bruyn H. Modern implant dentistry based on osseointegration: 50 years of progress, current trends and open questions. *Periodontol* 2000 2017;73:7-21.
- Araújo MG, Lindhe J. Dimensional ridge alterations following tooth extraction. An experimental study in the dog. *J Clin Periodontol* 2005;32:212-8.
- Denissen HW, Kalk W, Veldhuis HA, van Waas MA. Anatomic consideration for preventive implantation. *Int J Oral Maxillofac Implants* 1993;8:191-6.
- Trombelli L, Farina R, Marzola A, Bozzi L, Liljenberg B, Lindhe J. Modeling and remodeling of human extraction sockets. *J Clin Periodontol* 2008;35:630-9.
- Denardi RJ, da Silva RD, Thomé G, Andrighetto AR, de Freitas RM, Shimizu RH, *et al.* Bone response after immediate placement of implants in the anterior maxilla: A systematic review. *Oral Maxillofac Surg* 2019;23:13-25.
- Zhou X, Yang J, Wu L, Tang X, Mou Y, Sun W, *et al.* Evaluation of the effect of implants placed in preserved sockets versus fresh sockets on tissue preservation and esthetics: A meta-analysis and systematic review. *J Evid Based Dent Pract* 2019;19:101336.
- Canellas JV, Medeiros PJ, Figueredo CM, Fischer RG, Ritto FG. Which is the best choice after tooth extraction, immediate implant placement or delayed placement with alveolar ridge preservation? A systematic review and meta-analysis. *J Craniomaxillofac Surg* 2019;47:1793-802.
- Cosyn J, De Lat L, Seyssens L, Doornewaard R, Deschepper E, Vervaeke S. The effectiveness of immediate implant placement for single tooth replacement compared to delayed implant placement: A systematic review and meta-analysis. *J Clin Periodontol* 2019;46 Suppl 21:224-41.
- Palarie V, Bicer C, Lehmann KM, Zahalka M, Draenert FG, Kämmerer PW. Early outcome of an implant system with a resorbable adhesive calcium-phosphate coating—A prospective clinical study in partially dentate patients. *Clin Oral Investig* 2012;16:1039-48.
- Smeets R, Stadlinger B, Schwarz F, Beck-Broichsitter B, Jung O, Precht C, *et al.* Impact of dental implant surface modifications on osseointegration. *Biomed Res Int* 2016;2016:1-16.
- Aita H, Hori N, Takeuchi M, Suzuki T, Yamada M, Anpo M, *et al.* The effect of ultraviolet functionalization of titanium on integration with bone. *Biomaterials* 2009;30:1015-25.
- Gao Y, Liu Y, Zhou L, Guo Z, Rong M, Liu X, *et al.* The effects of different wavelength UV photofunctionalization on micro-arc oxidized titanium. *PLoS One* 2013;8:e68086.
- Altmann B, Kohal RJ, Steinberg T, Tomakidi P, Bächle-Haas M, Wennerberg A, *et al.* Distinct cell functions of osteoblasts on UV-functionalized titanium- and zirconia-based implant materials are modulated by surface topography. *Tissue Eng Part C Methods* 2013;19:850-63.
- Park KH, Koak JY, Kim SK, Han CH, Heo SJ. The effect of ultraviolet-C irradiation via a bactericidal ultraviolet sterilizer on an anodized titanium implant: A study in rabbits. *Int J Oral Maxillofac Implants* 2013;28:57-66.
- Minamikawa H, Ikeda T, Att W, Hagiwara Y, Hirota M, Tabuchi M, *et al.* Photofunctionalization increases the bioactivity and osteoconductivity of the titanium alloy Ti6Al4V. *J Biomed Mater Res A* 2014;102:3618-30.
- Funato A, Yamada M, Ogawa T. Success rate, healing time, and implant stability of photofunctionalized dental implants. *Int J Oral Maxillofac Implants* 2013;28:1261-71.
- Funato A, Ogawa T. Photofunctionalized dental implants: A case series in compromised bone. *Int J Oral Maxillofac Implants* 2013;28:1589-601.
- Ogawa T. Ultraviolet photofunctionalization of titanium implants. *Int J Oral Maxillofac Implants*. 2014;29:e95-102.
- Suzuki S, Kobayashi H, Ogawa T. Implant stability change and osseointegration speed of immediately loaded photofunctionalized implants. *Implant Dent* 2013;22:481-90.
- Arora NS, Ramanayake T, Ren YF, Romanos GE. Platelet-rich plasma: A literature review. *Implant Dent* 2009;18:303-10.
- Miron RJ, Zucchelli G, Pikos MA, Salama M, Lee S, Guillemette V, *et al.* Use of platelet-rich fibrin in regenerative dentistry: A systematic review. *Clin Oral Investig* 2017;21:1913-27.
- Stähli A, Strauss FJ, Gruber R. The use of platelet-rich plasma to enhance the outcomes of implant therapy: A systematic review. *Clin Oral Implants Res* 2018;29 Suppl 18:20-36.
- Strauss FJ, Stähli A, Gruber R. The use of platelet-rich fibrin to enhance the outcomes of implant therapy: A systematic review. *Clin Oral Implants Res* 2018;29 Suppl 18:6-19.
- Moher D. CONSORT: An evolving tool to help improve the quality of reports of randomized controlled trials. *Consolidated standards of reporting trials. JAMA* 1998;279:1489-91.
- Ohyama T, Uchida T, Shibuya N, Nakabayashi S, Ishigami T, Ogawa T. High bone-implant contact achieved by photofunctionalization to reduce periimplant stress: A three-dimensional finite element analysis. *Implant Dent* 2013;22:102-8.
- Greene JC, Vermillion JR. The oral hygiene index: A method for classifying oral hygiene status. *J Am Dent Assoc* 1960;61:172-9.
- Fu PS, Wu YM, Tsai CF, Wang JC, Huang TK, Chen WC, *et al.* Immediate implant placement following minimally invasive extraction: A case report with a 6-year follow-up. *Kaohsiung J Med Sci* 2011;27:353-6.
- Fürhauser R, Florescu D, Benesch T, Haas R, Mailath G, Watzek G.

- Evaluation of soft tissue around single-tooth implant crowns: The pink esthetic score. *Clin Oral Implants Res* 2005;16:639-44.
30. Belser UC, Grütter L, Vailati F, Bornstein MM, Weber HP, Buser D. Outcome evaluation of early placed maxillary anterior single-tooth implants using objective esthetic criteria: A cross-sectional, retrospective study in 45 patients with a 2- to 4-year follow-up using pink and white esthetic scores. *J Periodontol* 2009;80:140-51.
  31. Hof M, Umar N, Budas N, Seemann R, Pommer B, Zechner W. Evaluation of implant esthetics using eight objective indices-comparative analysis of reliability and validity. *Clin Oral Implants Res* 2018;29:697-706.
  32. Emami E, Cerutti-Kopplin D, Menassa M, Audy N, Kodama N, Durand R, *et al.* Does immediate loading affect clinical and patient-centered outcomes of mandibular 2-unsplinted-implant overdenture? A 2-year within-case analysis. *J Dent* 2016;50:30-6.
  33. Schneider CA, Rasband WS, Eliceiri KW. NIH Image to ImageJ: 25 years of image analysis. *Nat Methods* 2012;9:671-5.
  34. Mahoorkar S, Bhat S, Kant R. Single implant supported mandibular overdenture: A literature review. *J Indian Prosthodont Soc* 2016;16:75-82.
  35. Siaw YK. Achieving the optimal esthetic outcome of anterior restorations: Traditional or digital approach? *J Indian Prosthodont Soc* 2018;18:S3-4.
  36. Jayaraman S. Intervention for replacing missing teeth: Alveolar ridge preservation techniques for dental implant site development – Evidence summary of Cochrane review. *J Indian Prosthodont Soc* 2015;15:381-5.
  37. Ostman PO, Hellman M, Wendelhag I, Sennerby L. Resonance frequency analysis measurements of implants at placement surgery. *Int J Prosthodont* 2006;19:77-83.
  38. Misch CE, Perel ML, Wang HL, Sammartino G, Galindo-Moreno P, Trisi P, *et al.* Implant success, survival, and failure: The international congress of oral implantologists (ICOI) pisa consensus conference. *Implant Dent* 2008;17:5-15.
  39. Marx RE, Carlson ER, Eichstaedt RM, Schimmele SR, Strauss JE, Georgeff KR. Platelet-rich plasma: Growth factor enhancement for bone grafts. *Oral Surg Oral Med Oral Pathol Oral Radiol Endod* 1998;85:638-46.
  40. Thor A, Wannfors K, Sennerby L, Rasmusson L. Reconstruction of the severely resorbed maxilla with autogenous bone, platelet-rich plasma, and implants: 1-year results of a controlled prospective 5-year study. *Clin Implant Dent Relat Res* 2005;7:209-20.
  41. Hasegawa M, Hotta Y, Hoshino T, Ito K, Komatsu S, Saito T. Long-term radiographic evaluation of risk factors related to implant treatment: Suggestion for alternative statistical analysis of marginal bone loss. *Clin Oral Implants Res* 2016;27:1283-9.
  42. Kitajima H, Ogawa T. The use of photofunctionalized implants for low or extremely low primary stability cases. *Int J Oral Maxillofac Implants* 2016;31:439-47.
  43. Mehl C, Kern M, Neumann F, Bähr T, Wiltfang J, Gassling V. Effect of ultraviolet photofunctionalization of dental titanium implants on osseointegration. *J Zhejiang Univ Sci B* 2018;19:525-34.
  44. Bornstein MM, Hart CN, Halbritter SA, Morton D, Buser D. Early loading of nonsubmerged titanium implants with a chemically modified sand-blasted and acid-etched surface: 6-month results of a prospective case series study in the posterior mandible focusing on peri-implant crestal bone changes and implant stability quotient (ISQ) values. *Clin Implant Dent Relat Res* 2009;11:338-47.
  45. Hicklin SP, Schneebeli E, Chappuis V, Janner SF, Buser D, Brägger U. Early loading of titanium dental implants with an intra-operatively conditioned hydrophilic implant surface after 21 days of healing. *Clin Oral Implants Res* 2016;27:875-83.
  46. Chen ST, Buser D. Esthetic outcomes following immediate and early implant placement in the anterior maxilla – A systematic review. *Int J Oral Maxillofac Implants* 2014;29 (Supplement):186-215.

### Author Help: Online submission of the manuscripts

Articles can be submitted online from <http://www.journalonweb.com>. For online submission, the articles should be prepared in two files (first page file and article file). Images should be submitted separately.

1) **First Page File:**

Prepare the title page, covering letter, acknowledgement etc. using a word processor program. All information related to your identity should be included here. Use text/rtf/doc/pdf files. Do not zip the files.

2) **Article File:**

The main text of the article, beginning with the Abstract to References (including tables) should be in this file. Do not include any information (such as acknowledgement, your names in page headers etc.) in this file. Use text/rtf/doc/pdf files. Do not zip the files. Limit the file size to 1 MB. Do not incorporate images in the file. If file size is large, graphs can be submitted separately as images, without their being incorporated in the article file. This will reduce the size of the file.

3) **Images:**

Submit good quality color images. Each image should be less than 4096 kb (4 MB) in size. The size of the image can be reduced by decreasing the actual height and width of the images (keep up to about 6 inches and up to about 1800 x 1200 pixels). JPEG is the most suitable file format. The image quality should be good enough to judge the scientific value of the image. For the purpose of printing, always retain a good quality, high resolution image. This high resolution image should be sent to the editorial office at the time of sending a revised article.

4) **Legends:**

Legends for the figures/images should be included at the end of the article file.